

Postmenopausal Vaginal Atrophy: Non-hormonal therapy with a moisturizing bioadhesive vaginal gel

By Alessandro D. Genazzani and Massimo Milani *

Obstetrics and Gynecology Clinic, University of Modena

** Mipharm Research and Development Center, Milan*

Introduction

Vaginal atrophy (VA) is an irreversible involution of the mucous membranes and tissues of the vagina following the drop in estrogen that commonly occurs in women during menopause (1). Due to a lengthening of the average lifespan and longer life expectancy after menopause, vaginal atrophy is destined to become a clinical problem with an increasingly greater epidemiological significance. It is a known fact that the urogenital epithelium is sensitive to the action of estrogens. The reduction in the circulating levels of these hormones brings about the onset of atrophy and a thinning of the vaginal and urethral mucous membrane (2). Vaginal atrophy has substantial repercussions of a genuinely pathological nature because it facilitates urogenital infections and, at the same time, impacts a woman's quality of life during menopause by altering relations with her partner due to dyspareunia (3). Vaginal atrophy generally occurs with a sensation of dryness and burning, often also accompanied by itching, and urogenital infections are not uncommon (4). About 40% of menopausal women present with vaginal atrophy (1) and this incidence rises as the period of menopause grows longer. The physiopathological condition of vaginal atrophy is sustained by a thinning of the mucous membrane epithelium, with a reduction in secretions of the glandular epithelia in turn due to reduced hydration and loss of vaginal texture and elasticity. Typically, the vaginal pH during menopause tends toward values considerably higher than those observed during fertility (5). This increased pH in combination with an estrogen deficiency can in turn promote profound modifications of the vaginal bacterial flora, making bacterial forms of vaginal infections more frequent.

For this reason, both systemic and vaginal estrogen or estroprogestin replacement therapy is a rational approach to the problem of vaginal atrophy. However, estrogen therapy is not always the only solution to the problem. The average duration of hormone replacement therapy, starting with the beginning of menopause, is not adequate in many cases to keep the problem of vaginal atrophy under control over the long term. 25% of menopausal women who take hormone replacement therapy continue to present with the signs and symptoms of vaginal atrophy (6). Furthermore, the use of estrogens by vaginal route is often characterized by reduced patient compliance. Considering that systemic hormone replacement therapy is contraindicated in a large percentage of women (due to a history of cancer or thromboembolism, etc.), it is clear that a non-hormonal alternative to the treatment of vaginal atrophy is a valid solution, especially in the case of topical products with a moisturizing action targeting the mucous membranes. Precisely for this reason, this study looks into the pharmacological properties and clinical efficacy of a bioadhesive gel based on polycarbophil-carbophol (Replens®) with a specific indication of efficacy in the treatment of postmenopausal vaginal atrophy and dryness.

Properties of the bioadhesive vaginal gel

The polycarboxophil-carboxophil-based vaginal gel has a high level of bioadhesiveness capable of ensuring a prolonged moisturizing action on the epithelium of the vaginal mucous membrane (7). Bioadhesiveness is a property that allows a compound to adhere to the surface of the body's mucous membranes by means of non-covalent bonds (vaginal, oral, and intestinal mucous membranes). This gel is capable of adhering to the vaginal mucous membrane thanks to the presence of two characteristic polyacid polymers having a high molecular weight and a molecular structure very similar to that of the vaginal mucus: polycarboxophil and carboxophil. Experimental studies (8) have shown that this gel has the greatest capacity for bioadhesiveness to the vaginal epithelium compared to other topical vaginal products used for the treatment of vaginal atrophy (Figure 1).

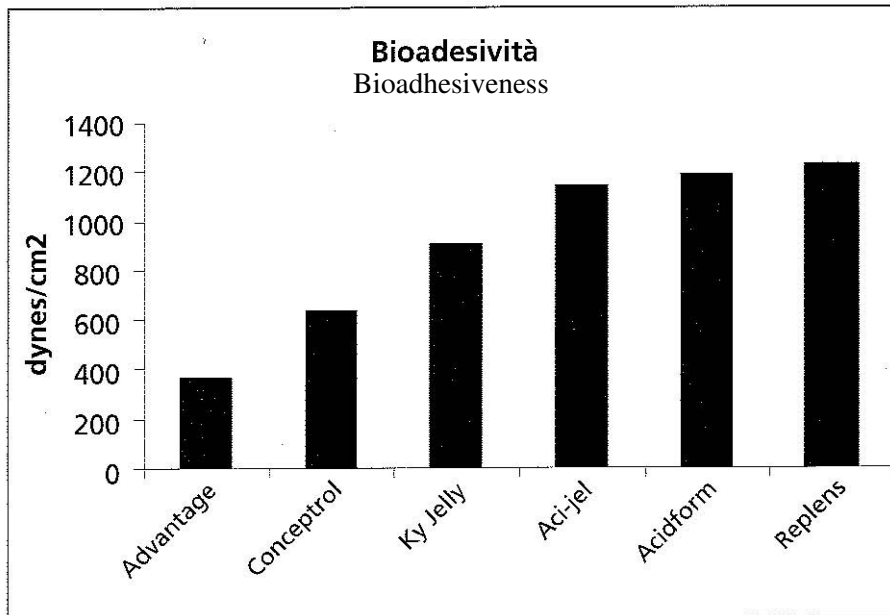


FIGURA 1. Valutazione della Bioadesività di differenti prodotti per uso vaginale (Garg S et al 2001)

Figure 1. Evaluation of the bioadhesiveness of various products for vaginal use (Garg S et al. 201)

Furthermore, polycarboxophil and carboxophil are substances with a buffering action and their use women experiencing menopause either naturally or as a result of surgery has led to a correction of the vaginal pH values comparable to those obtained with hormone replacement therapy (9) (Figure 2). This substance is not only capable of producing a vaginal pH correction action, but also a direct cellular “moisturizing” action resulting from an increased flow of H₂O molecules from the outside to the inside of the cells on the surface of the vaginal mucous membrane. This movement of water into the cells of the vaginal epithelium is promoted by the particular unique structure of the polymers in this gel. From a physiological standpoint, these effects translate into an increase in the maturation index (10) of the vaginal epithelium and the amount of moisturizing of the vaginal mucous membrane in women with vaginal atrophy (11) treated with the polycarboxophil-carboxophil-based gel (Figures 3 and 4).

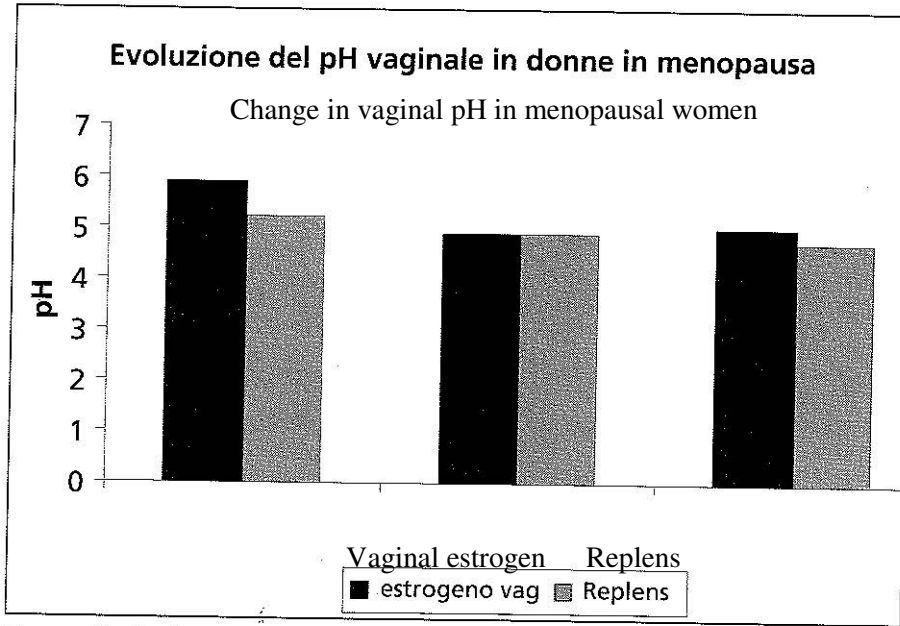


FIGURA 2. Evoluzione del pH vaginale in donne in menopausa in trattamento con estrogeno per via vaginale o con Replens (Bygdeman M. et al 1996)

Figure 2. Change in vaginal pH in menopausal women receiving vaginal-route estrogen therapy or Replens therapy (Bygdeman M. et al. 1996)

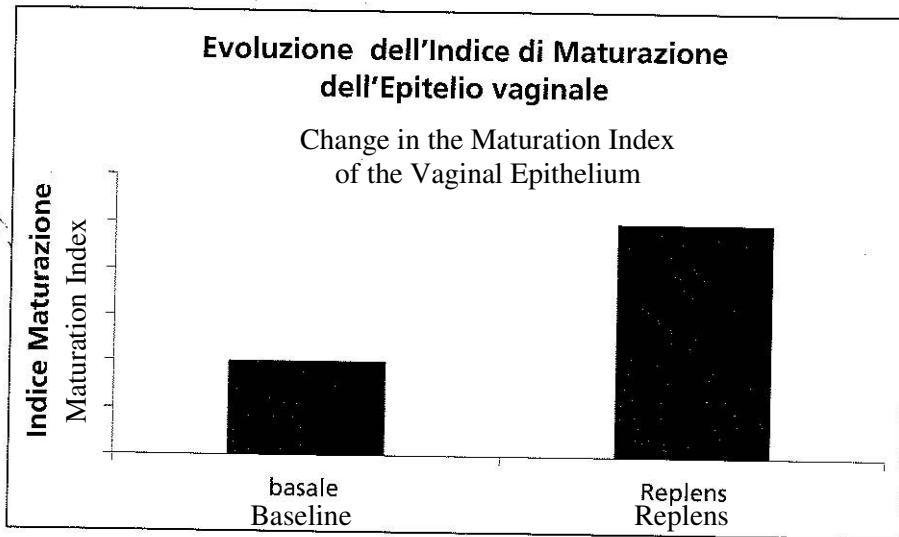


FIGURA 3. Evoluzione dell'indice di maturazione dell'epitelio vaginale. Valutazione citologica. (Van Der Laak et al.2002)

Figure 3. Change in the maturation index of vaginal epithelium. Cytological evaluation (Van Der Laak et al. 2002)

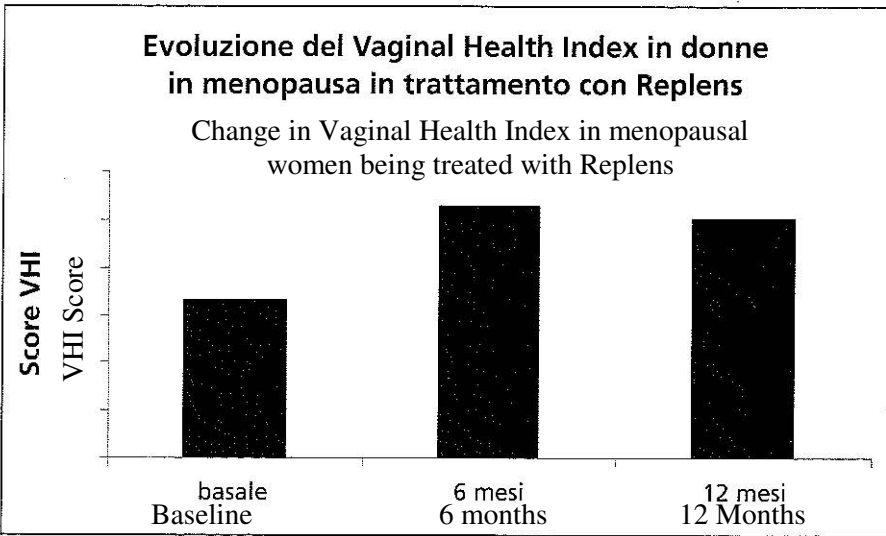


FIGURA 4. Evoluzione del vaginal Health Index score in donne in menopausa e atrofia vaginale (Nightingall et al 1994)

Figure 4. Change in the Vaginal Health Index score in menopausal women with vaginal atrophy (Nightingall et al. 1994)

Non-hormonal therapy for vaginal atrophy: clinical efficacy of treatment with the polycarbophil-carbophol-based gel

The clinical efficacy of the gel has thus far been evaluated in 9 controlled clinical trials enrolling a total of 530 women, 399 of which with VA due to natural menopause and 131 of which with VA following surgical menopause. The duration of the treatment ranged from a minimum of 4 weeks to a maximum of 24. The efficacy at a dose of 2.5 g applied every 3 days was compared both to a placebo (3 studies) and to estrogens by vaginal route (4 studies) or acid douches (2 studies). Compared to a placebo, the treatment with a gel based on polycarbophil-carbophol shows an improvement in both symptoms (dyspareunia, dryness, itching, and irritation) and VA-related signs (cellular maturation index by PAP smear). The gel significantly reduced the vaginal pH levels compared to the baseline (from values of 5.6 to values of 4.6 after treatment), comparable to those found with vaginally administered estrogens (4.7 versus 4.9, respectively). Furthermore, after treatment for 16 weeks of women with a history of breast cancer, the vaginal pH dropped from 6.9 ± 0.1 to 4.1 ± 0.07 . The treatment also significantly improved the overall vaginal dryness score (vaginal elasticity, secretion volume, and appearance/integrity of the mucous membrane), going from a value of 10 ± 0.4 to a value of 24 ± 0.3 after treatment. Among menopausal women receiving raloxifene therapy, treatment with this gel improved the signs and symptoms of vaginal atrophy with an efficacy comparable to that of vaginally-applied estrogens (12). One study evaluated the effects of this substance on the microcirculatory flow of the vaginal mucous membrane through a Laser Doppler sensor in 10 women with vaginal atrophy due to natural menopause showing a significant increase of 25% in microcirculatory blood flow over the baseline (from 163 IU to 204 IU) among women with and without hormone replacement therapy (Figure 5). The increase in blood flow, which improves the metabolism of the epithelial layers of the vaginal mucous membrane, may assist in reestablishing the hydration and elasticity of the vaginal mucous membrane. In conclusion, the results of these studies show

that Replens® is an efficacious non-hormonal topical treatment for vaginal atrophy in women experiencing natural or surgical menopause, whether they are receiving hormone replacement therapy or not. The mechanisms of action (bioadhesiveness, buffering effect, “direct” cellular hydration, and blood circulation beneath the mucous membrane) of this vaginal gel are specific and characteristic and closely linked to the physical and chemical properties of the two polymers it contains. In women with vaginal atrophy, this gel is an effective, valid, safe, and well-tolerated non-hormonal alternative to estrogen therapy in all clinical situations in which the use of estrogens may be contraindicated or not practical or not relatively effective.

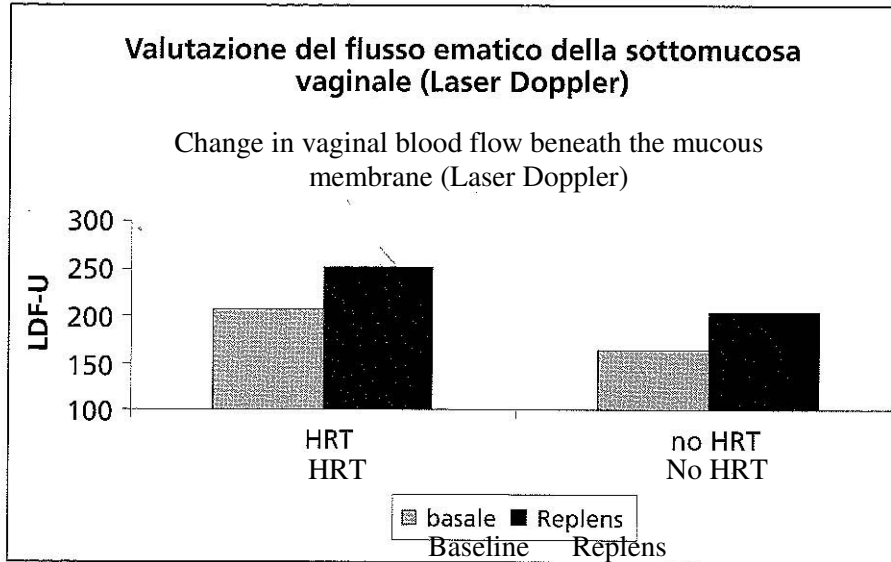


FIGURA 5. Valutazione del flusso ematico della sottomucosa vaginale in donne in menopausa in trattamento HRT e non

Figure 5. Change in vaginal blood flow beneath the mucous membrane in menopausal women with and without HRT

Bibliography
[already in English]

BIBLIOGRAFIA

1. Van Der Laak et al. The Effect of Replens on vaginal cytology in the treatment of post menopausal atrophy: cytomorphology versus computerised cytometry. J clin Pathol 2002; 55:446-451
2. Nachtingall L. Comparative study: Replens versus local estrogen in menopausal women. Fertility and Sterility 1994; 61:178-180
3. Parsons A. et al. Effect of Raloxifene on the response to conjugated estrogen vaginal cream or non hormonal moisturizers in postmenopausal vaginal atrophy. Obstet Gynecool 2003; 101:346-352
4. Iosif SC et al. Prevalence of genito-urinary symptoms in the late menopause. Acta Obstet Gynecol Scand 1984; 63:257-60
5. Samsioe B. Urogenital aging. A hidden problem. Am J Obstet Gynecol 1998; 178:S245-S249
6. Willhite LA. Urogenital atrophy: prevention and treatment. Pharmacotherapy. 2001, 21:464-80
7. Gelfand M. Treating vaginal dryness in breast cancer patients : Results of applying a polycarbophil moisturizing gel. J Women Health, 1994; 6:427-434
8. Garg S et al. Properties of a new acid-buffering bioadhesive vaginal formulation. Contraception 2001; 64:67-75
9. Bygdeman M. Replens versus dienestrol cream in symptomatic treatment of vaginal atrophy in postmenopausal women. Maturitas 1996; 23:259-263
10. Van Der Laak et al. The Effect of Replens on vaginal cytology in the treatment of post menopausal atrophy: cytomorphology versus computerised cytometry. J clin Pathol 2002; 55:446-451
11. Nachtingall L. Comparative study: Replens versus local estrogen in menopausal women. Fertility and Sterility 1994; 61:178-180
12. Parsons A. et al. Effect of Raloxifene on the response to conjugated estrogen vaginal cream or non hormonal moisturizers in postmenopausal vaginal atrophy. Obstet Gynecool 2003; 101:346-352